

Interactive CardioVascular and Thoracic Surgery

Inflammatory pseudotumour of the lung

Maruthi Vara Prasad, Roy Thankachen, Bhawna Parihar and Vinayak Shukla
Interact CardioVasc Thorac Surg 2004;3:323-325
DOI: 10.1016/j.icvts.2003.11.018

The online version of this article, along with updated information and services, is located on
the World Wide Web at:

<http://icvts.ctsnetjournals.org/cgi/content/full/3/2/323>

Interactive Cardiovascular and Thoracic Surgery is the official journal of the European Association for
Cardio-thoracic Surgery (EACTS) and the European Society for Cardiovascular Surgery (ESCVS).
Copyright © 2004 by European Association for Cardio-thoracic Surgery. Print ISSN: 1569-9293.



ELSEVIER

Interactive Cardiovascular and Thoracic Surgery 3 (2004) 323–325

INTERACTIVE
CARDIOVASCULAR AND
THORACIC SURGERY

www.icvts.org

Case report - Pulmonary

Inflammatory pseudotumour of the lung

Maruthi Vara Prasad, Roy Thankachen, Bhawna Parihar, Vinayak Shukla*

Department of Cardiothoracic Surgery, Christian Medical College Hospital, Vellore 632004, Tamil Nadu, India

Received 7 August 2003; received in revised form 26 September 2003; accepted 11 November 2003

Abstract

Inflammatory pseudotumours of the lungs have rarely been reported. These have been described as a benign entity of unknown origin and are often locally invasive requiring extensive pulmonary resection. We present a 12-year-old boy with fever and massive haemoptysis who was found to have a well defined left-sided paracardiac mass lesion on chest X-ray and CT scan thorax. A CT-guided fine needle aspiration cytology was reported as inflammatory pseudotumour. As a result of recurrent episodes of massive haemoptysis during admission the child underwent an emergency left posterolateral thoracotomy and excision of the mass along with a left pneumonectomy. The biopsy of the mass was conclusive. Postoperatively the child was ventilated over night and was extubated the next day. He has been doing well on follow-up. Based on our case report and on other similar reports it would appear that the primary treatment of inflammatory pseudotumors of the lung is surgical. Complete resection is the key to prevent recurrence and the prognosis is excellent following surgery.

© 2004 Elsevier B.V. All rights reserved.

Keywords: Inflammatory pseudotumours; Lung

1. Introduction

Inflammatory pseudotumours of the lungs are rare. They are prominent among the large solitary intrapulmonary lesions in children. This is a benign entity of unknown origin and are often locally invasive requiring extensive pulmonary resection [1]. Complete resection is advocated to prevent local recurrence and leads to excellent survival.

2. Clinical summary

A 12-year-old boy was admitted with complaints of low-grade fever and productive cough. While in hospital he developed severe haemoptysis. The examination of the respiratory system revealed diminished air entry on the left side. The examination of other systems was unremarkable. His pulmonary function test suggested moderate restrictive ventilatory defect in the left lung. His chest X-ray showed a well-defined round homogenous paracardiac mass lesion measuring $12 \times 12 \text{ cm}^2$ (Fig. 1). There was no evidence of mediastinal shift. There were a few areas of calcification

within the lesion. CT scan confirmed the findings (Fig. 2). A CT-guided fine needle aspiration cytology was done which was reported as an inflammatory pseudotumour.

During the hospital stay he had an episode of massive haemoptysis and hence was taken up for an emergency surgery. Immediately after intubation he had another bout of massive haemoptysis. The chest was entered through a left posterolateral thoracotomy incision. The mass was occupying almost the entire hemithorax. The consistency was hard and it was diffusely calcified. There were a few nodes at the hilum which were significantly enlarged and also calcified. Access to the hilum was almost impossible. The pericardium was incised an inch anterior to the phrenic nerve and stay sutures taken. The left pulmonary artery was isolated and divided between ligatures. He had a single pulmonary vein draining the left lung. This was isolated and divided between ligatures. The atrial end was oversewn with prolene. The left main bronchus was then divided and the tumour was then removed along with the left lung. The bronchial stump was repaired and the chest was closed with a single drain. The child had to be ventilated overnight and was extubated the next morning. He was discharged after 12 days and has been doing well on follow-up.

Histopathological examination of the left lung was reported as inflammatory pseudotumour.

* Corresponding author. Tel.: +91-416-2222-102x2186/2106; fax: +91-416-2232-035.

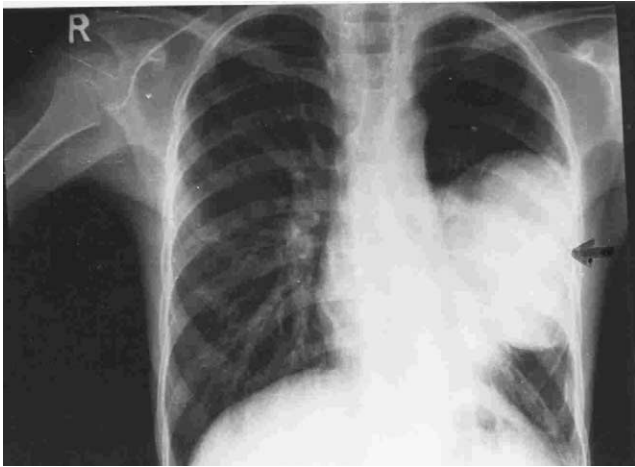


Fig. 1. Chest X-ray showing well defined paracardiac mass.

3. Discussion

The true incidence of inflammatory pseudotumour is difficult to establish because of various nomenclatures used. Bahadori and Liebow [2] in their review found that inflammatory pseudotumours represented the most common isolated primary tumour-like lesions of the lung among children under 16 years of age. Monzan [3] in his review of paediatric cases found that 59% of children had symptoms. Cough and fever were the most frequent symptoms. Other symptoms noticed were weight loss, haemoptysis, chest pain and respiratory tract infections. Inflammatory pseudotumours are benign inflammatory masses that have been observed virtually in every organ system but most often described in the lung [4]. Rare cases have been reported in which the brain and spinal cord are affected [5]. Inflammatory pseudotumour is considered to be a rare benign neoplastic lesion consisting mainly of spindle mesenchymal cells [6].

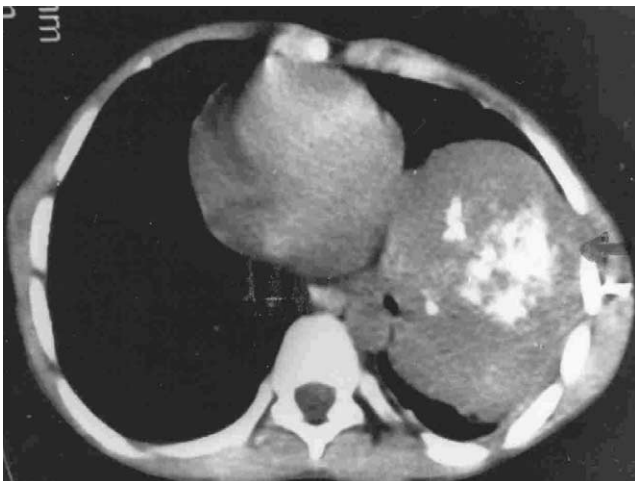


Fig. 2. CT scan showing homogenous well circumscribed lesion.

Although roentgenographic examination of the chest defined the lesion adequately, no specific signs suggest the diagnosis of inflammatory pseudotumour [7]. A solitary circumscribed mass of round or oval shape within the lung was the most common radiological presentation. Calcification and cavitations were noted infrequently. Computed tomography done in cases reported earlier in the literature and also in our case was not very helpful in defining the nature of the lesion [3]. CT-guided biopsy of the lesion however proved to be conclusive in this case.

Cerfolio and Allen [1] have demonstrated that there are two types of pseudotumours. The first type is called the noninvasive inflammatory pseudotumour which occurs in an asymptomatic patient and is characterized by a small lesion that does not invade surrounding structures and is usually easily removed by wedge resection. The second is called invasive inflammatory tumour of the lung. It usually occurs in younger patients with systemic symptoms of fever, fatigue or weight loss. It is usually large and may invade local mediastinal structures or the chest wall and may require extensive surgery. However, the extent of resection can be decided by the peroperative findings.

Treatment of inflammatory pseudotumours of the lung is surgery. Complete resection remains the key to prevent recurrence [1]. The prognosis of patients with inflammatory tumours is excellent [8].

References

- [1] Cerfolio RJ, Allen MS, Nascimento AG, Deschamps C, Trastek VF, Miller DL, Pairolero PC. Inflammatory pseudotumours of the lung. *Ann Thorac Surg* 1999;67:933–6.
- [2] Bahadori M, Liebow AA. Plasma cell granulomas of the lung. *Cancer* 1973;31:191–208.
- [3] Monzon CM, Gilchrist GS, Burgert EO, O'Connell EJ, Telander RL, Hoftman AD, Li CY. Plasma cell granuloma of the lung in children. *Pediatrics* 1982;70:268–74.
- [4] Tan-Liu NS, Matsubara O, Grillo HC, Mark EJ. Invasive fibrous tumor of the tracheobronchial tree: clinical and pathological study of seven cases. *Hum Pathol* 1989;20:180–4.
- [5] Tresser M, Rolf C, Cohen M. Plasma cell granulomas of the brain. *Childs Nerv Syst* 1996;12(1):52–7.
- [6] Dehabreh J, Zisis C, Arnoyianni N, Katis K, Jurbrail D, Charalambos Z, Niki A, Konstantinos K. Inflammatory pseudotumour. *Eur J Cardiothorac Surg* 1999;16(6):670–3.
- [7] Hadimeri U, Hadimeri H, Resjo M. Inflammatory pseudotumour of the lung. *Pediatr Radiol* 1993;23(8):624–5.
- [8] Kumar A, Sethi GR, Kapoor R, Chopra K, Malhotra V, Khanna SK, Gaiind B. Pseudotumor [plasma cell granuloma] of the lung. *Indian Paediatr* 1990;27:741–4.

Appendix A. ICVTS on-line discussion

Author: Dr. Sameh Sersar, Mansoura University, Department of Cardiothoracic Surgery, Mansoura, 123 Egypt

Date: 11-Feb-2004

Message: I read with interest this interesting subject.

I have two comments. Inflammatory pseudotumor is extremely difficult to differentiate from solitary fibrous tumor of the pleura. This needs cytoimmunohistochemistry. Inflammatory pseudotumor is negative for CD34 and Cytokeratin while solitary fibrous tumor of the pleura is positive for CD34 and mesothelioma is positive for Cytokeratin [1].

Inflammatory pseudotumor was called childhood fibrous tumor with psammoma bodies by Rostenthal and Abdul Karim, by Jeong et al. calcifying fibrous tumor [2].

References

- [1] Flint A and Weiss SW. CD34 and keratin distinguishes solitary fibrous tumor (fibrous mesothelioma) of the pleura from desmoplastic mesothelioma. *Hum. Pathol*; 26: 428–31; 1995.
- [2] Jeong IS, Lee JK, Sung R, Ahn JH and Song HG. Calcifying pseudotumor of the mediastinum; A case report. *JKMS*,12;58–62; 1997.

Inflammatory pseudotumour of the lung
Maruthi Vara Prasad, Roy Thankachen, Bhawna Parihar and Vinayak Shukla
Interact CardioVasc Thorac Surg 2004;3:323-325
DOI: 10.1016/j.icvts.2003.11.018

This information is current as of February 23, 2007

Updated Information & Services	including high-resolution figures, can be found at: http://icvts.ctsnetjournals.org/cgi/content/full/3/2/323
Subspecialty Collections	This article, along with others on similar topics, appears in the following collection(s): Lung - other http://icvts.ctsnetjournals.org/cgi/collection/lung_other
Permissions & Licensing	Requests to reproducing this article in parts (figures, tables) or in its entirety should be submitted to: icvts@ejcts.ch
Reprints	For information about ordering reprints, please email: icvts@ejcts.ch

Interactive CardioVascular and Thoracic Surgery