



## Inhibin is more specific than calretinin as an immunohistochemical marker for differentiating sarcomatoid granulosa cell tumour of the ovary from other spindle cell neoplasms

V I Shah, O N Freites, P Maxwell and W G McCluggage

*J. Clin. Pathol.* 2003;56:221-224  
doi:10.1136/jcp.56.3.221

---

Updated information and services can be found at:  
<http://jcp.bmj.com/cgi/content/full/56/3/221>

---

*These include:*

### Rapid responses

You can respond to this article at:  
<http://jcp.bmj.com/cgi/eletter-submit/56/3/221>

### Email alerting service

Receive free email alerts when new articles cite this article - sign up in the box at the top right corner of the article

---

### Topic collections

Articles on similar topics can be found in the following collections

[Histopathology](#) (997 articles)  
[Cancer: gynecological](#) (252 articles)

---

### Notes

---

To order reprints of this article go to:  
<http://www.bmjournals.com/cgi/reprintform>

To subscribe to *Journal of Clinical Pathology* go to:  
<http://www.bmjournals.com/subscriptions/>

## ORIGINAL ARTICLE

# Inhibin is more specific than calretinin as an immunohistochemical marker for differentiating sarcomatoid granulosa cell tumour of the ovary from other spindle cell neoplasms

V I Shah, O N Freites, P Maxwell, W G McCluggage

*J Clin Pathol* 2003;56:221–224

See end of article for authors' affiliations

Correspondence to:  
Dr V Shah, Department of  
Histopathology, Singleton  
Hospital, Sketty, Swansea  
SA2 8QA, Wales, UK;  
varsha.shah@  
swansea-tr.wales.nhs.uk

Accepted for publication  
31 October 2002

**Aims:** To describe a case of recurrent sarcomatoid adult granulosa cell tumour (AGCT) of the ovary and to evaluate the usefulness of two ovarian sex cord stromal markers (inhibin and calretinin) in separating sarcomatoid AGCT from true sarcomas.

**Methods:** A 72 year old woman presented with a recurrent sarcomatoid AGCT in the sigmoid colon mesentery, which histologically mimicked a malignant gastrointestinal stromal tumour (GIST). This index case and 79 sarcomas (32 GISTs, 28 leiomyosarcomas, 15 endometrial stromal sarcomas (ESSs), including one with sex cord-like areas, and four undifferentiated uterine sarcomas) were immunostained using antibodies to inhibin and calretinin.

**Results:** The recurrent sarcomatoid AGCT expressed diffuse, strong cytoplasmic immunoreactivity with inhibin and focal but strong nuclear and cytoplasmic positivity with calretinin. Focal, weak cytoplasmic inhibin expression limited to sex cord-like areas was present in one ESS. None of the other sarcomas expressed inhibin. Focal, strong calretinin immunoreactivity was identified in 11 leiomyosarcomas and one GIST. The case of ESS with sex cord-like areas showed strong immunoreactivity for calretinin limited to the sex cord-like areas.

**Conclusions:** Inhibin is a useful immunomarker to distinguish sarcomatoid AGCT from other spindle cell neoplasms that may enter into the differential diagnosis. Calretinin appears to be less specific than inhibin.

The clinical course of adult granulosa cell tumour (AGCT) of the ovary is typically characterised by delayed recurrences or metastases.<sup>1</sup> The histological patterns of AGCT are varied, with the sarcomatoid pattern being uncommon. Sarcomatoid AGCT may be misinterpreted as a sarcoma, particularly when it recurs at a site distant from the ovary, and the pathologist is unaware of the history of a primary ovarian tumour in the distant past.

Inhibin, a dimeric 32 kDa peptide hormone composed of an  $\alpha$  subunit and a  $\beta$  subunit is produced by ovarian granulosa and theca cells. Several studies have found antibodies against inhibin, especially against the  $\alpha$  subunit, to be useful immunohistochemical markers for granulosa cell tumours.<sup>2–4</sup> The only study that specifically looked at the differential diagnosis of sarcomatoid AGCT concluded that  $\alpha$  inhibin was useful in differentiating sarcomatoid variants of AGCT from leiomyomatous tumours and haemangiopericytomas.<sup>5</sup> However, the specificity of inhibin with regard to other spindle cell neoplasms that may mimic sarcomatoid AGCT is uncertain.

"Sarcomatoid adult granulosa cell tumour may be misinterpreted as a sarcoma, particularly when it recurs at a site distant from the ovary, and the pathologist is unaware of the history of a primary ovarian tumour in the distant past"

Calretinin, a 29 kDa calcium binding protein best known for its role in the diagnosis of mesothelioma, has also been suggested as an immunohistochemical marker for ovarian sex cord stromal tumours.<sup>6–9</sup> However, calretinin positivity has been demonstrated in a small number of benign spindle cell neoplasms and sarcomas.<sup>10–14</sup>

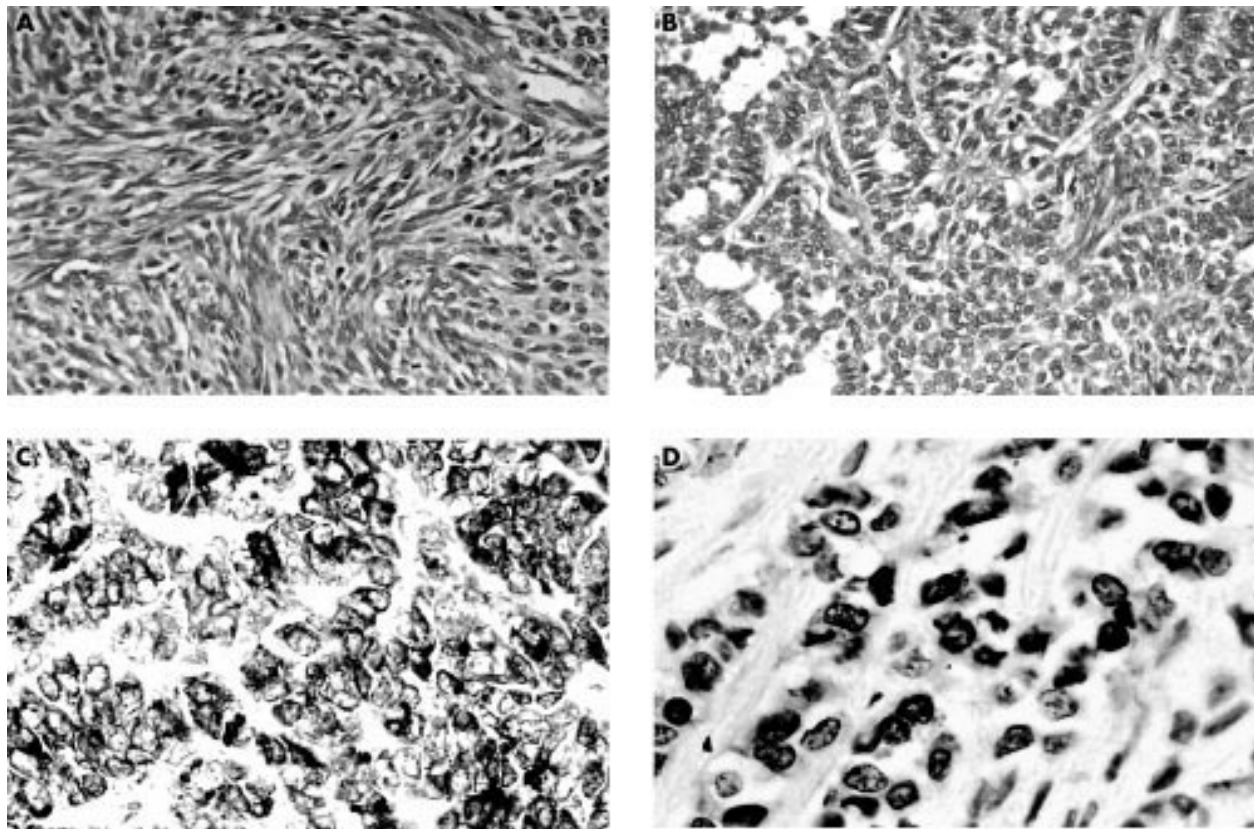
In our study, we describe a case of a recurrent sarcomatoid AGCT that clinically mimicked a primary colonic tumour and histologically was suggestive of a malignant gastrointestinal stromal tumour (GIST), and evaluate the usefulness of antibodies against inhibin and calretinin in differentiating sarcomatoid AGCT from various sarcomas.

## MATERIALS AND METHODS

### Index case

A 72 year old woman had a sarcomatoid AGCT of the left ovary resected followed by treatment with two courses of platinum based chemotherapy and radiotherapy. She re-presented four years later with a large mass in the sigmoid colon mesentery, which was clinically and radiologically felt to be a primary colonic tumour. A segmental resection of the sigmoid colon revealed a 9 × 8 × 4 cm necrotic grey/white soft tumour in the mesentery. Initial histological examination revealed a predominantly sarcomatoid tumour with moderate nuclear pleomorphism, brisk mitotic activity (eight to nine mitoses/10 high power fields) and foci of necrosis, reminiscent of a malignant GIST (fig 1A). In view of the clinical history of an AGCT of the ovary, further sections were examined and these revealed focal areas of insular, ribbon-like, cystic and follicular patterns with some nuclear grooving (fig 1B). These typical areas were very sparse and were found only after extensive sampling. The histological appearances

**Abbreviations:** AGCT, adult granulosa cell tumour; GIST, gastrointestinal stromal tumour; ESS, endometrial stromal sarcoma



**Figure 1** Recurrent adult granulosa cell tumour. (A) Sarcomatoid area (haematoxylin and eosin stained). (B) Insular, ribbon-like and follicular patterns (haematoxylin and eosin stained). (C) Sarcomatoid area showing diffuse, strong cytoplasmic inhibin immunoreactivity. (D) Sarcomatoid area showing focal, strong nuclear and cytoplasmic calretinin immunoreactivity.

in conjunction with the immunostaining results (discussed below) were interpreted as recurrent sarcomatoid AGCT.

### Specimens

Formalin fixed, paraffin wax embedded blocks of 79 sarcomas (32 GISTs, 28 leiomyosarcomas (20 uterine, two retroperitoneal, two colonic, one urinary bladder, two skin, and one larynx), 15 endometrial stromal sarcomas (one with sex cord-like areas), and four undifferentiated uterine sarcomas) were retrieved from the histology files of the departments of pathology, Swansea NHS Trust and Royal Group of Hospitals Trust, Belfast. The histological diagnosis was confirmed by review of haematoxylin and eosin stained sections and representative blocks were selected for immunohistochemistry.

### Immunohistochemical staining

Sections were cut on to coated slides (Sigma, Poole, Dorset, UK) and dried overnight at 37°C. Endogenous peroxidase activity was blocked by 3% alcoholic hydrogen peroxide for 10 minutes. Sections were pretreated in an 850 W domestic microwave oven in citrate buffer (pH 6.0) for 20 minutes and allowed to cool for 20 minutes. Sections were incubated for 60 minutes with mouse monoclonal antibody to human inhibin 32 kDa  $\alpha$  subunit (1/50 dilution; Serotec, Oxford, UK) and with polyclonal anticalretinin (1/50 dilution; Zymed, San Francisco, California, USA). Localisation was performed using Envision peroxidase (Dako, Ely, Cambridgeshire, UK). Diaminobenzidine (Dako) was used as the chromogen.

Negative controls, where the primary antiserum was omitted and replaced with mouse or rabbit immunoglobulin (Dako), were included. Positive controls for each antibody were also included. These comprised ovaries containing follicular cysts for anti-inhibin and a mesothelioma with known immunoreactivity for anticalretinin.

## RESULTS

### Index case

The tumour cells showed diffuse, strong cytoplasmic immunoreactivity with antibodies against vimentin and inhibin (fig 1C), focal, strong, membranous positivity with pancytokeratin specific antibody, and focal, strong, nuclear and cytoplasmic positivity with the antibody to calretinin (fig 1D). There was no expression of epithelial membrane antigen,  $\alpha$  smooth muscle actin, desmin, HHF-35, or CD34.

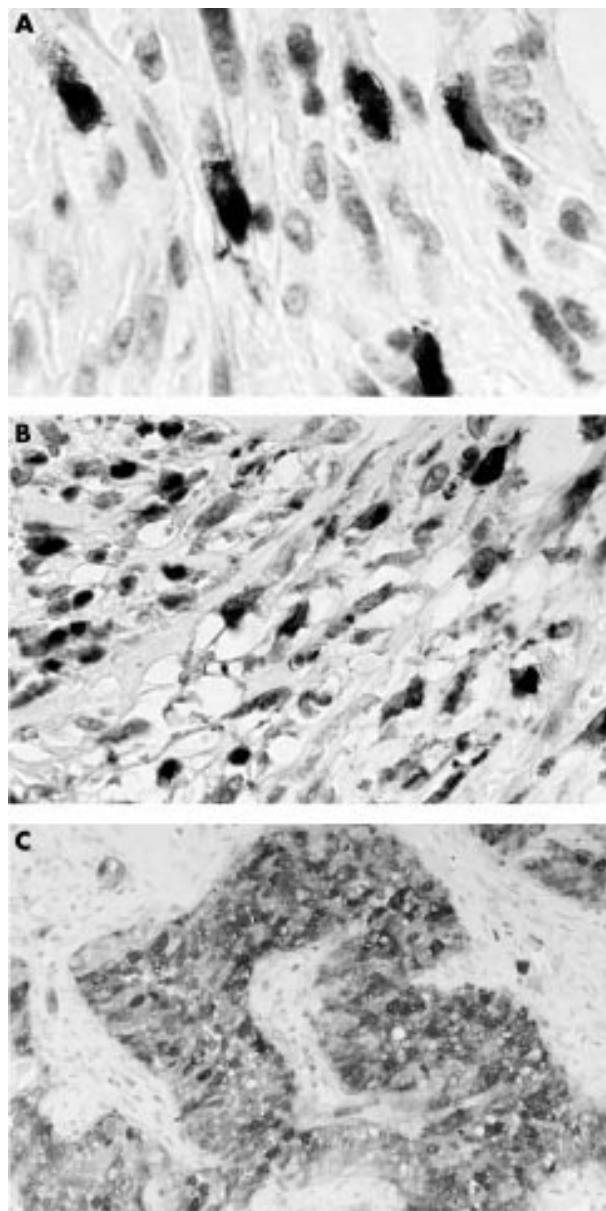
### Sarcomas

Thirteen cases (one GIST, 11 leiomyosarcomas (seven uterine; one each of colon, skin, retroperitoneum, and urinary bladder) and one endometrial stromal sarcoma (ESS) with sex cord-like areas) showed moderate to strong, focal (< 25% tumour cells) cytoplasmic and nuclear staining for calretinin, with the immunoreactivity in ESS limited to sex cord-like areas (fig 2). All sarcomas were immunonegative for inhibin except for one case of ESS, which showed focal, weak cytoplasmic immunoreactivity limited to the associated sex cord-like areas.

## DISCUSSION

The sarcomatoid variant of an ovarian AGCT may mimic a variety of sarcomas. Flemming *et al* reported three cases of metastatic sarcomatoid AGCT (two in the liver and one in the left abdominal region) that had been misinterpreted as haemangiopericytoma or leiomyosarcoma by several pathologists.<sup>5</sup> Our index case of recurrent sarcomatoid AGCT in the sigmoid colon mesentery resembled a primary colonic tumour clinically and radiologically, and a malignant GIST by routine histology.

In general, immunohistochemical staining with antibodies against epithelial and mesenchymal antigens is of little value



**Figure 2** Calretinin immunoreactivity in spindle cell neoplasms. (A) Focal, strong positivity in a gastrointestinal stromal tumour. (B) Focal, strong positivity in uterine leiomyosarcoma. (C) Strong positivity in a sex cord-like area in endometrial stromal sarcoma.

in differentiating sarcomatoid AGCT from genuine sarcomas because none of these markers is specific for AGCT. However, inhibin and calretinin have been reported to be useful markers for AGCT. Fleming *et al* were the first to use antibodies against inhibin to stain tissue sections of ovarian tumours, and they found positive staining in all AGCTs and in all three cases of late metastases of sarcomatoid AGCT.<sup>5</sup> Similarly, in our index case, the diagnosis of recurrent sarcomatoid AGCT was established by positive immunostaining for inhibin. Our case of sarcomatoid AGCT was also focally but strongly immunoreactive with the antibody against calretinin.

"In our experience, calretinin is less specific because 13 of 79 sarcomas studied expressed calretinin"

Because the diagnosis of AGCT has important therapeutic implications, the immunomarkers used for the differentiation of sarcomatoid AGCT from genuine sarcomas should be

#### Take home messages

- Inhibin is useful as an immunomarker to distinguish sarcomatoid adult granulosa cell tumour from other spindle cell neoplasms because none of the other sarcomas tested expressed inhibin, except for one endometrial stromal sarcoma (ESS), which showed focal, weak cytoplasmic inhibin expression limited to sex cord-like areas
- Calretinin appears to be less specific than inhibin because focal, strong calretinin immunoreactivity was identified in 11 leiomyosarcomas and one gastrointestinal stromal tumour. In addition, the case of ESS with sex cord-like areas showed strong immunoreactivity for calretinin limited to the sex cord-like areas.

specific. Both inhibin and calretinin have been shown to be sensitive markers of AGCT.<sup>2-5 7-9</sup> Inhibin is thought to be relatively specific in that other ovarian tumours that may mimic sex cord stromal neoplasms are generally negative.<sup>2</sup> However, there is little information in the literature regarding inhibin and calretinin staining in extraovarian neoplasms that may mimic sarcomatoid AGCT. In our study, all the 79 sarcomas lacked immunoreactivity for inhibin except for one case of ESS that showed focal, weak positivity limited to associated sex cord-like areas. Inhibin positivity in the sex cord-like areas of ESS has been described previously, and would suggest that these areas represent true sex cord differentiation in ESS.<sup>15-17</sup> Our results are also similar to those of Fleming *et al*, who found no expression of inhibin in the small number of sarcomas (three haemangiopericytomas and four leiomyomatous tumours) studied.<sup>5</sup> Thus, inhibin immunoreactivity in a spindle cell neoplasm should suggest sarcomatoid AGCT.

It has been suggested that calretinin is a slightly more sensitive marker than inhibin for ovarian sex cord stromal tumours.<sup>9</sup> However, in our experience, calretinin is less specific because 13 of 79 sarcomas studied expressed calretinin. There are conflicting data in the literature regarding calretinin expression in spindle cell neoplasms. In the study by Attanoos *et al* none of the 30 spindle cell neoplasms expressed calretinin,<sup>18</sup> but other studies have reported calretinin expression in a variety of spindle cell neoplasms, including synovial sarcoma, malignant peripheral nerve sheath tumour, solitary fibrous tumour, and cardiac myxoma.<sup>10-14</sup> Hence, calretinin positivity in spindle cell neoplasms must be interpreted with caution.

In summary, we conclude that inhibin is a useful immunohistochemical marker to differentiate sarcomatoid AGCT from other spindle cell neoplasms. Calretinin appears to be a less specific marker than inhibin, but may be of value in this differential diagnosis because it has been reported to be more sensitive in AGCT. With a sarcomatoid tumour at any site in a patient with a history of an ovarian tumour in the past, sarcomatoid AGCT should be included in the differential diagnosis and appropriate immunohistochemical studies performed.

#### NOTE IN EDITING

Since the submission of this paper, Movhedi-Lankarani and Kurman have reported a comparison of calretinin and inhibin immunostaining in 215 ovarian tumours. They concluded that calretinin is a more sensitive but less specific marker than  $\alpha$  inhibin for ovarian sex cord stromal neoplasms.<sup>19</sup>

#### ACKNOWLEDGEMENT

We thank Dr RB Denholm, Department of Pathology, Carmarthen and District NHS Trust for providing the slides of the primary ovarian AGCT for review.

.....  
**Authors' affiliations**

**V I Shah**, Department of Histopathology, Singleton Hospital, Sketty, Swansea SA2 8QA, Wales, UK

**O N Freites**, Department of Gynaecology and Obstetrics, Singleton Hospital

**P Maxwell, W G McCluggage**, Department of Histopathology, Royal Groups of Hospitals Trust, Belfast, Northern Ireland, UK

**REFERENCES**

- 1 **Scully RE**, Young RH, Clement PB. Sex cord-stromal tumours, granulosa cell tumours. In: Rosai J, ed. *Atlas of tumour pathology*. 3rd Series. Fascicle 23. Washington DC: Armed Forces Institute of Pathology, 1998:169–88.
- 2 **McCluggage WG**. Recent advances in immunohistochemistry in the diagnosis of ovarian neoplasms. *J Clin Pathol* 2000;**53**:327–34.
- 3 **McCluggage WG**. The value of inhibin staining in gynaecological pathology. *Int J Gynecol Pathol* 2001;**20**:79–89.
- 4 **McCluggage WG**, Maxwell P, Sloan JM. Immunohistochemical staining of ovarian granulosa cell tumours with monoclonal antibody against inhibin. *Hum Pathol* 1997;**28**:1034–8.
- 5 **Flemming P**, Wellmann A, Maschek H, et al. Monoclonal antibodies against inhibin represent key markers of adult granulosa cell tumours of the ovary even in their metastases. *Am J Surg Pathol* 1995;**19**:927–33.
- 6 **Dogliani C**, Dei Tos AP, Laurino L. Calretinin: a novel immunocytochemical marker for mesothelioma. *Am J Surg Pathol* 1996;**20**:1037–46.
- 7 **McCluggage WG**, Maxwell P. Immunohistochemical staining for calretinin is useful in the diagnosis of ovarian sex cord-stromal tumours. *Histopathology* 2001;**38**:403–8.
- 8 **Cao QJ**, Jones JG, Li M. Expression of calretinin in human ovary, testis, and ovarian sex cord-stromal tumors. *Int J Gynecol Pathol* 2001;**20**:346–52.
- 9 **Deavers MT**, Malpica A, Liu J, et al. Ovarian sex cord-stromal tumours: an immunohistochemical study including a comparison of calretinin with inhibin [abstract]. *Mod Pathol* 2002;**15**:194A.
- 10 **Cappello F**, Bellafiore M, Bucchieri F, et al. Poorly differentiated synovial sarcoma: a case report. *Pathol Oncol Res* 2001;**7**:63–6.
- 11 **Miettinen M**, Limon J, Niezabitowski A, et al. Calretinin and other mesothelioma markers in synovial sarcoma: analysis of antigenic similarities and differences with malignant mesothelioma. *Am J Surg Pathol* 2001;**25**:610–17.
- 12 **Lee JR**, Hancock SM, Martindale RG. Solitary fibrous tumors arising in abdominal wall hernia sacs. *Am Surg* 2001;**67**:577–81.
- 13 **Terracciano LM**, Mhawek P, Suess K, et al. Calretinin as a marker for cardiac myxoma. Diagnostic and histogenetic considerations. *Am J Clin Pathol* 2000;**114**:754–9.
- 14 **Acebo E**, Val-Bernal JF, Gomez-Roman JJ. Thrombomodulin, calretinin and c-kit (CD117) expression in cardiac myxoma. *Histol Histopathol* 2001;**16**:1031–6.
- 15 **Krishnamurthy S**, Jungbloth AA, Busam KJ, et al. Uterine tumors resembling ovarian sex-cord tumors have an immunophenotype consistent with true sex-cord differentiation. *Am J Surg Pathol* 1998;**22**:1078–82.
- 16 **Baker RJ**, Hildebrandt RH, Rouse RV, et al. Inhibin and CD99 (MIC2) expression in uterine stromal neoplasms with sex cord-like elements. *Hum Pathol* 1999;**30**:671–9.
- 17 **McCluggage WG**. Uterine tumours resembling ovarian sex cord tumours: immunohistochemical evidence for true sex cord differentiation. *Histopathology* 1999;**34**:373–80.
- 18 **Attanoos RL**, Dojcinov SD, Webb R, et al. Anti-mesothelial markers in sarcomatoid mesothelioma and other spindle cell neoplasms. *Histopathology* 2000;**37**:224–31.
- 19 **Movhedi-Lankarani S**, Kurman RJ. Calretinin, a more sensitive but less specific marker than alpha-inhibin for ovarian sex cord-stromal neoplasms: an immunohistochemical study of 215 cases. *Am J Surg Pathol* 2002;**26**:1477–83.



Reference linking to full text  
of more than 200 journals

**Toll free links**

You can access the FULL TEXT of articles cited in the *Journal of Clinical Pathology* online if the citation is to one of the more than 200 journals hosted by HighWire (<http://highwire.stanford.edu>) without a subscription to that journal. There are also direct links from references to the Medline abstract for other titles.

**[www.jclinpath.com](http://www.jclinpath.com)**